



GIG  
CYMRU  
NHS  
WALES

Archwiliadau Corfforol  
ar gyfer Babanod a Babanod  
Newydd-anedig Cymru  
Newborn and Infant  
Physical Examination Cymru



Llywodraeth Cymru  
Welsh Government

# New-born and Infant Examination Cymru (NIPEC) 2023

## Examination of the Eyes



# Contents

---

## Examination of the Eyes

Incidence	3
Before the NIPEC eye examinations	4
Risk factors for congenital cataracts	4
Risk factors for other eye or visual problems	4
Undertaking the eye examination	5
NIPEC infant (6 week) eye examination	6
The fundal reflex examination	7
Congenital cataracts	8
Abnormality not suspected (normal fundal reflex assessment)	8
Abnormality suspected (abnormal fundal reflex assessment)	9
Parental concerns	9
Pathway	10

Elements of this guideline have been reproduced and adapted from the NIPE Programme Handbook 2021 with permission from the NIPE Programme Team, NHS England.

NHS England (2021) Newborn and infant physical examination screening programme handbook. Available at: [Newborn and infant physical examination \(NIPE\) screening programme handbook – GOV.UK \(www.gov.uk\)](https://www.gov.uk) (Accessed: 18th October 2023)

References to parent(s) also relate to carer(s), if appropriate.

# Examination of the Eyes

---

Eye development is complex, and a wide range of structural abnormalities may occur if the process is disturbed either due to genetic, infective, or sporadic causes.

The primary purpose of the NIPEC newborn and infant (6 week) eye examination is to identify congenital cataract(s). Some abnormalities, particularly congenital cataract, are treatable but require early detection, rapid referral and management to prevent lifelong visual impairment.

## Incidence

Around 2 to 3 in every 10,000 babies are born with cataracts. In over 50% of these, both eyes will be affected. One fifth of affected babies will have a family history of childhood cataracts. Cataract is the most common treatable cause of blindness in childhood in the UK and worldwide.

A congenital cataract is an opacity within the lens of the eye, which is located behind the pupil. It can occur in one or both eyes and range in severity. A severe cataract blocks light and images from reaching the retina, preventing visual pathway development at a critical stage. Although rare, it is the most common, treatable, visually significant condition identified during NIPEC eye examination.

The practitioner should be alert to risk factors, such as a genetic syndrome, pre-natal infection, sensorineural hearing loss, neurodevelopmental issues or a family history of an eye condition with onset in infancy or early childhood.

Babies with other eye abnormalities, incidental findings or risk factors identified at the NIPEC newborn or infant (6 week) examination should be referred for specialist review according to locally agreed pathways.

Please note the guidance below relates to both the NIPEC newborn and infant (6 week) eye examinations unless otherwise stated.

# Examination of the Eyes

---

## Before the NIPEC eye examinations

Before the examinations, practitioners should:

- **discuss the test and gain consent from the parents to undertake the examination**
- **establish the mother's recent obstetric history**
- **establish if there are any clinical risks for eye disorders (see below).**

## Risk factors for congenital cataracts

Babies with a family history of bilateral congenital or hereditary cataracts in a first-degree relative are at risk of developing early cataracts. Even if the NIPEC examination is normal, these babies may be considered for referral for early specialist opinion, via locally agreed pathways.

## Risk factors for other eye or visual problems

Risk factors include:

- **a family history of bilateral congenital or hereditary cataracts affecting a first-degree relative**
- **a first-degree relative with an ocular condition which was congenital or developed in early childhood, for example aniridia (absent iris), coloboma (malformation of the eye) or retinoblastoma (malignant retinal tumour) childhood**
- **small size for gestational age or preterm birth – Babies born before 31 weeks gestation or under 1500g are screened for retinopathy of prematurity. There is a higher incidence of refractive errors (needing glasses), strabismus (turn in eye) and vision problems reported in premature babies**
- **genetic syndromes, such as trisomy 21, associated with eye and vision disorders**
- **port wine stain involving the eyelids, which can cause glaucoma**
- **maternal exposure to viruses during pregnancy, including rubella and cytomegalovirus**
- **maternal exposure to certain drugs (eg opiates) can result in delayed visual maturation**
- **neurodevelopmental conditions or sensorineural hearing loss (deafness caused by abnormal nerve function in the inner ear).**

Although practitioners should be aware of these risk factors, they do not alter the NIPEC national eye examination pathway. Babies identified with such risk factors should be managed via locally agreed pathways.

# Examination of the Eyes

---

## Undertaking the eye examination

The primary aim of the NIPEC eye examination is the detection of congenital cataracts. In addition, it is considered good practice to include assessment of the:

- **eyelids, to exclude malformation and skin abnormality**
- **baby's ability to fully open the eyelids**
- **both eyes the same size**
- **symmetry and clarity of the cornea (the cornea is the circular transparent window of the eye through which the iris and pupil can be seen - its diameter in a term baby should be similar to the width of the practitioner's little fingertip)**
- **the roundness and symmetry of the pupils.**

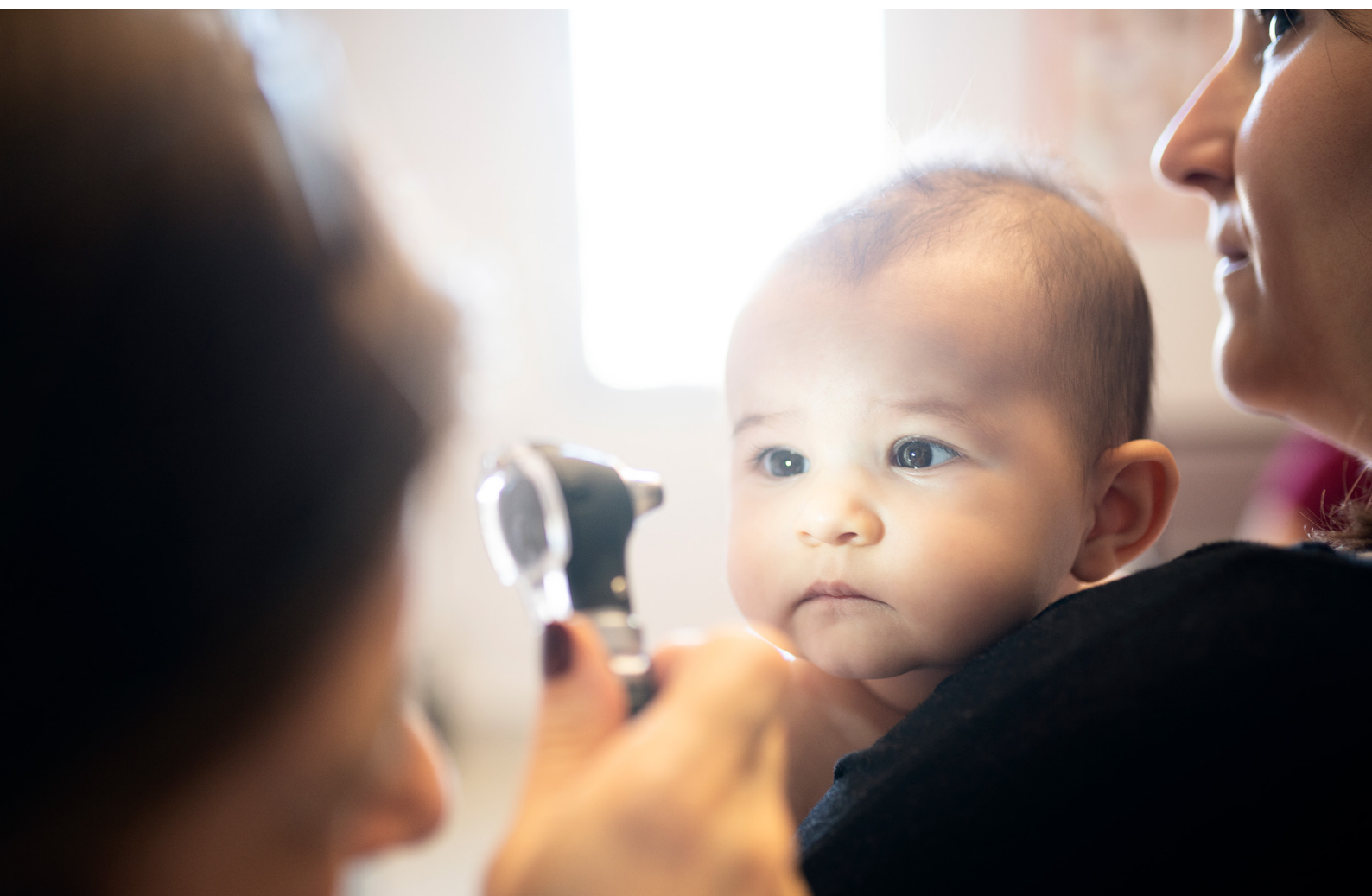# Examination of the Eyes

---

## NIPEC infant (6 week) eye examination

In addition to the assessment described for the newborn eye examination, the infant (6 week) eye examination should also include checking:

- if the parents have any concerns about the baby's visual behaviour, for example asking if the baby looks at them steadily and has started smiling back at them
- the ability of the baby to fixate the practitioner's face steadily, without nystagmus (wobble of the eyes)
- the ability of the baby to fix and follow a large, bright target by moving their eyes (not just by moving their head)
- the alignment of the eyes, which can be variable at this age but a consistently and significantly deviated eye is not normal.



# Examination of the Eyes

## The fundal reflex examination

The fundal reflex should be assessed. This is the normal reflection of white light from the back of the eye on ophthalmoscopy which varies in colour depending on the baby's ethnicity.

**Please note:** The reflex for this screening is predominantly referred to as 'fundal reflex'. Fundal reflex can also be referred to as red or fundus in other NHS resources.

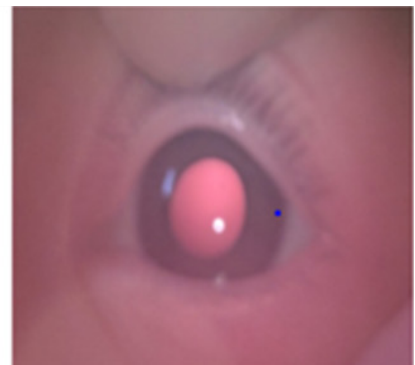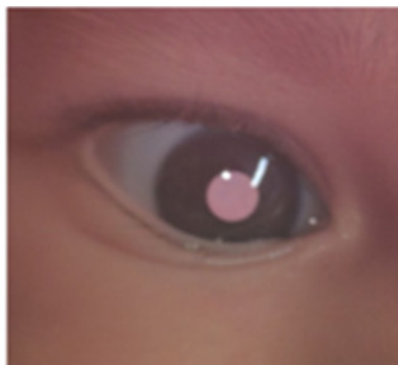
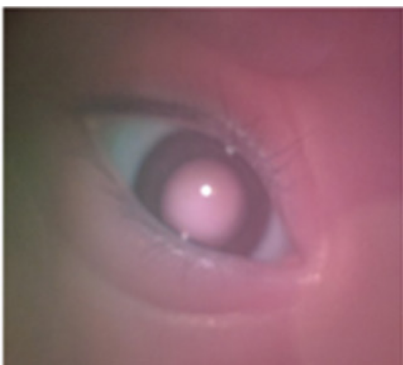
To undertake the examination, the practitioner should:

- **dim the overhead lights and make sure that the baby is settled**
- **hold the eyepiece of the ophthalmoscope up to his or her eye, at arm's length from the baby's face**
- **direct the circle of light from the ophthalmoscope towards the baby's eye while gently parting the baby's eyelids, if necessary**
- **view the fundal reflex through the ophthalmoscope eyepiece – the fundal reflex should be the same in both eyes for colour, brightness, and the presence of any shadows.**

The examination can be repeated by an experienced practitioner if the examination is equivocal. This should ideally be within the 72-hour guideline period of the NIPEC newborn examination.

The normal fundal reflex varies in hue depending on the baby's ethnicity. White babies have an orange-red reflex. The reflex can be less bright and appear magnolia in colour in black, Asian or minority ethnic babies. If the assessment is difficult, it can help to assess the baby's parents' fundal reflexes to determine the expected reflex colour.

Examples of normal fundal reflex by ethnicity of baby (from left to right: black, Asian, white).

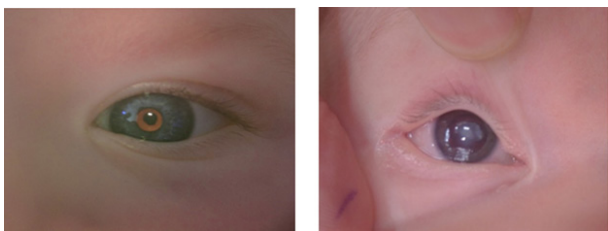

# Examination of the Eyes

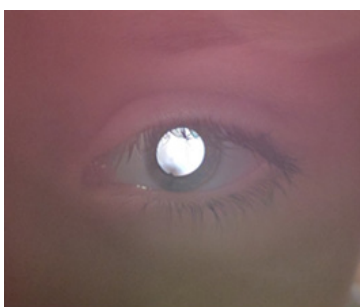
## Congenital cataracts

Congenital cataracts cause a central shadow, completely obscure the fundal reflex, or may make the reflex in one eye appear duller than the other. A severe cataract can make the pupil appear white when viewed with the naked eye.

The fundal reflex is abnormal if it is completely or partially obscured, is abnormal in shape (iris coloboma or aniridia), white or asymmetrical in colour or brightness to the other eye.



Examples of partially (left) and completely (right) obscured fundal reflexes.



An example of a white 'fundal reflex'.

## Abnormality not suspected (normal fundal reflex assessment)

Babies with no abnormality suspected for the NIPEC newborn examination should have the NIPEC infant (6 week) examination at 6 weeks of age. Infants with no abnormality suspected for the NIPEC infant (6 week) examination should be offered the Healthy Child Wales Programme [An overview of the Healthy Child Wales Programme \(gov.wales\)](https://gov.wales).

Babies with no abnormality suspected during the examination but with risk factors described above may be referred via locally agreed pathways.

Some babies will need regular monitoring even if the examination shows no evidence of an ocular problem. These children will normally be under the care of a paediatrician and an ophthalmology review should be sought as per local protocol. This would include babies with:

- **Neurological/neurodevelopmental conditions**
- **Sensorineural hearing impairment**
- **Chromosomal abnormalities, such as trisomy 21.**

All eye images are reproduced with kind permission of Miss Louise Allen, Consultant Paediatric Ophthalmologist, Cambridge University Hospital Trust

# Examination of the Eyes

---

## Abnormality suspected (abnormal fundal reflex assessment)

Babies with an abnormality suspected following **newborn examination** should be referred promptly and assessed by a consultant ophthalmologist or paediatric ophthalmology service **within 2 weeks of examination**.

However, if there are significant concerns at the time of the NIPEC newborn examination, discussion with the consultant-led ophthalmology service before the baby's discharge home should be considered.

Surgery for severe cataract is usually undertaken between 6 to 10 weeks of age for optimal visual outcome.

Babies with an abnormality suspected following **infant (6 week) examination** should be referred promptly and assessed by a consultant ophthalmologist or paediatric ophthalmology service **within 2 weeks of examination**.

## Parental concerns

Parents should contact their midwife, GP, optometrist, or health visitor whenever they have any concerns about their baby's eyes or visual behaviour, including:

- **inability of their baby to fully open their eyes or if eyelid opening appears asymmetrical**
- **apparent deterioration of visual interest**
- **a wobbling of the eyes**
- **a consistent eye misalignment**
- **an abnormal appearance of the eyes**
- **a white reflex, consistently seen on flash photography**
- **asymmetry of the fundal reflex, consistently seen on flash photography.**

Note that a family history of an eye or vision condition developing later in life does not require a neonatal referral to ophthalmic services.

Other eye abnormalities should be managed according to local referral pathways.

